



HEMATOLOGICAL EVALUATION OF A PATIENT WITH *Histoplasma capsulatum* INFECTION

Eliana Rezende Adami^{a,d}, Tiago Alapenha de Lira^b, Railson Hannenberg^a, Joao Luiz Coelho Ribas^c

^a Department of Clinical Analysis, Federal University of Paraná, Curitiba, PR, Brazil

^b Pharmaceutical of CPML - Center of Pathology and Medicine, University of Alagoas, AL, Brazil.

^c Department of Industrial Biotechnology, Universidade Positivo, Curitiba, PR, Brazil

^d Department of Biomedicine, Universidade Positivo, Department of Odontology, Universidade UniDombosco and Department of Pharmaceutical Uniandrade, Curitiba, PR, Brazil.

Corresponding autor: elianaradami@yahoo.com.br

RESUMO

A histoplasmose é uma doença fúngica sistêmica causada pelo fungo *Histoplasma capsulatum* e é considerada uma infecção oportunista relacionada a imunossupressão grave em pacientes com HIV/AIDS. A histoplasmose é uma das principais causas de morte em pessoas vivendo com HIV, superando até mesmo a tuberculose. Atualmente, o diagnóstico de histoplasmose é baseado em sinais e sintomas, como febre, sudorese noturna, fadiga, emagrecimento, náusea, vômitos e dispneia. Entretanto, esses sintomas são completamente inespecíficos, visto que podem ocorrer em outras doenças oportunistas como a tuberculose e a criptococose. Um diagnóstico definitivo baseia-se no isolamento e identificação de *H. capsulatum* por cultura ou por visualização direta dos fungos. A cultura é considerada o padrão-ouro mas pode levar de quatro a seis semanas para o resultado. Uma vez que esse fungo parasita os neutrófilos nas primeiras 24 horas; proliferando dentro dos macrófagos e se espalha para o hospedeiro através deles, torna-se fundamental o diagnóstico precoce e preciso através da análise da extensão sanguínea. Assim o objetivo é elaborar relato de caso para divulgar um caso clínico de histoplasma e alertar e orientar os profissionais de saúde para diagnóstico e auxiliar no manejo do paciente que através de diagnóstico precoce pode melhorar o prognóstico e qualidade de vida dos pacientes soro positivo portadores desse fungo.

Palavras-chave: *H. capsulatum*; Soro positivo; Hematologia; Infecção oportunista

ABSTRACT

Histoplasmosis is a systemic fungal disease caused by the fungus *Histoplasma capsulatum* and is considered an opportunistic infection related to severe immunosuppression in patients with HIV / AIDS. Histoplasmosis is a major cause of death in people living with HIV, even overcoming tuberculosis. Currently, the diagnosis of histoplasmosis is based on signs and symptoms, such as fever, night sweats, fatigue, weight loss, nausea, vomiting and dyspnoea. However, these symptoms are completely nonspecific, since they can occur in other opportunistic diseases such as tuberculosis and cryptococcosis. A definitive diagnosis is based on the isolation and identification of *H. capsulatum* by culture or by direct visualization of the fungi. The culture is considered the gold standard but it can take four to six weeks for the result. Since this fungus parasites neutrophils in the first 24 hours; proliferating within macrophages and spreading to the host through them, early and accurate diagnosis through blood extension analysis is essential. Thus, the objective is to prepare a case report to disseminate a clinical case of histoplasma and alert and guide health professionals for diagnosis and assist in the management of the patient, who, through early diagnosis, can improve the prognosis and quality of life of positive serum patients with this fungus.



Keywords: *H. capsulatum*; Positive serum;

Hematology; Opportunistic infection.

1 INTRODUCTION

Histoplasmosis is a systemic fungal disease caused by *Histoplasma capsulatum*, an opportunistic infection related to severe immunosuppression in patients with human immunodeficiency virus (HIV). Histoplasmosis is a major cause of death in people living with HIV. In endemic areas, histoplasmosis affects 2 to 5% of HIV-infected individuals. Depending on the region, this percentage may reach 25%, such as the Mississippi and Ohio valleys, in the USA¹. In 50 to 75% of cases, histoplasmosis is the first manifestation of AIDS. In HIV patients, *Histoplasma capsulatum* causes disseminated disease in 95% of cases, predominantly affecting individuals with a CD4 cell count below 200 / mm³. Its diagnosis requires a high index of clinical suspicion, since its manifestations can mimic a variety of opportune infections, such as *Pneumocystis carinii* pneumonia, tuberculosis and *Mycobacterium avium* complex infection². The report is justified by the low number of cases in the literature that report the presence of histoplasma in neutrophils, so the publication becomes relevant definitive diagnosis is based on the isolation and identification of *H. capsulatum* by culture or by direct visualization of the fungi. The culture is considered the gold standard, but it can take four to six weeks for the result. Since this fungus parasites neutrophils in the first 24 hours; proliferating within macrophages and spreading to the host through them, early and accurate diagnosis through analysis of blood extension is essential³. Thus, the objective of preparing this case report is to assist in the early diagnosis of this fungus, improving the prognosis and quality of life of positive serum patients with this fungus.

2 CASE REPORT

Male, JASS, aged 57, diabetic and HIV positive. He was admitted to the Hospital

School Helvio Auto (AL) on 02/07/2020, with reports diarrhea (about 6 episodes a day) and loss of appetite 20 days ago. Asthenia, sweating, asymptomatic dry cough and temperature 38.6 0C, Blood Pressure (BP) 100 x 70 mmHg, report of dyspnea on small efforts. Weight loss of 8-9 kg. Hydration was prescribed with 0.9% saline solution (SF), 500 MI intravenous serum (IV) every 6 h. Hydrocortisone succinate sodium of 100 mg was prescribed in an ampoule of 12/12 h. Azithromycin 500 mg 1 tablet 3 times a week (Monday, Tuesday and Wednesday), Albendazole 400 mg 1 oral tablet 24/24 h, Omeprazole 40 mg 1 ampoule EV 24/24 h, Captopril 25 mg 1 sublingual tablet 6 / 6 h if BP \geq 160 x 110 mmHg, Ondansetrone 2 mg / MI 1 ampoule 8/8 h, Dipyrone sodium 500 mg 1 ampoule EV slow. Measure capillary blood glucose of 6 / 6h and depending on the result, administer regular insulin following the guidelines: if the result is \leq 180 mg / DI do not administer, if it is between 181 to 200 mg / DI, administer 2 U, 201 to 250 mg / DI = 4 U, 251 to 300 mg / DI = 6 U, 301 to 350 mg / DI = 8 U, 351 to 400 mg / DI = 10 U and if > 400 mg / DI gives 12 U. The patient was not being treated with antiretroviral therapy (ART), reported abandonment due to depressive disorder after his mother's death. So Tenofovir 300 mg + Lamivudine 300 mg 1 oral tablet 24/24 h, Darunavir (DRV) 600 mg 1 oral tablet 12/12 h, Ritonavir (RTV) 100 mg 1 oral tablet 12/12 h was prescribed. Heart rate 28 rpm, blood saturation 98%. In addition, chest X-ray examinations showed infiltration in the left lung base, characteristic of pneumonia. Laboratory tests were performed at the time of admission on February 7 and on subsequent days, with results reported on Table 1; 24 and 02/29/2020. During hospitalization, the patient presented abnormal liver tests and C-reactive protein (PCR), anemia was found in the hemogram and in the slide microscopy, yeast elements compatible with *Histoplasma capsulatum* were found in the cytoplasm of neutrophils, with negative BAAR research,



this fungus parasites neutrophils in the first 24 hours; and proliferate within the macrophages spreading to the host through them (figure 1), after detection of *H capsulatum* amphotericin 35 mg / kg / day was prescribed. On February 24, the anemia condition was maintained, blood transfusion was performed and liver alterations were maintained with Aspartate aminotransferase (AST) 120 IU / L, Alanine aminotransferase (ALT) 144.30 IU / L, lactate dehydrogenase (LDH) 2,014.00 IU / L total bilirubin (BT) 1.57 mg / dL and PCR 157.36 mg / L. On 2/29/20 the patient still had anemia, with changes in TGO 769.10 mg / UI / L, ALT 182, 40 IU / L, PCR 157.11 mg / L, DLH 5.393.00 U / L, but the patient reported improvements in the general condition without fever, without diarrhea, improvement in sweating, the patient died on 02/29/20 due to disseminated histoplasmosis.

3 DISCUSSION

Disseminated histoplasmosis can affect HIV positive patients with high viral load, and in February 2020 the patient had a viral load (CV) of 1,3404.41, CD4 cells were not requested, thus he stands out as a candidate to be diagnosed by *H capsulatum*, regardless of occupation, origin and epidemiological history⁴. Histoplasmosis in HIV-infected patients can progress rapidly,

leading patients to death. Most patients have complaints related to tiredness, fatigue, fever, sweating, weight loss evident in the last 2 months^{2,5}. In the case reported, the patient had all of these symptoms with great weight loss of around 8-9 kg. In addition, studies show that respiratory complaints are reported by patients around 50%^{2,5}, the patient under study showed dyspnea in small efforts, characterizing breathing difficulties. Regarding gastrointestinal problems, 10 to 20% of the patients present changes^{2,5}, in the referred case the patient had bloody diarrhea for 20 days, around 6 episodes a day. In the case of Histoplasmosis, laboratory findings show persistent anemia, leukopenia, changes in liver function and elevation of LDH, this increase shows an important laboratory indicator finding, serving as an important complementary exam for the diagnosis of the disease⁶. In the study carried out, the hematological profile corroborates this information, as he presented leukopenia, anisocytosis +, mild microcytosis and normal platelets. As well as the biochemical profile that reported changes in liver tests (ALT, AST and Bilirubins), kidney (urea and creatinine) and DLH value of 5393.00 UL. In addition, imaging results demonstrate pulmonary infiltration⁶ confirmed in our chest X-ray findings. The diagnosis of histoplasmosis is performed by visualizing the fungus in the

Figura 1 - Hematological microscopy photos

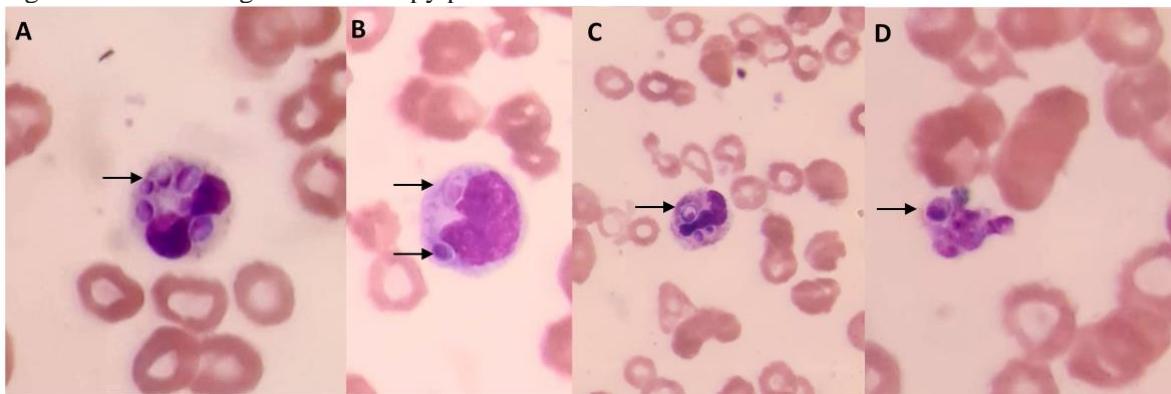


Figure 1. Hematological microscopy photos. Panel (A), (B), (C) and (D) show the *H capsulatum* within the leukocytes.



Table 1 - Hematological and biochemical profile

	02/07/2020	02/24/2020	02/29/2020
Erythrogram			
Erythrocytes (millions/mm ³)	2.9	2.52	2.77
Hemoglobin (g/dL)	8.8	6,9	7.3
Hematocrit (%)	24.7	19.5	21.5
MCV (fL)	85.17	77.38	77.61
MCH (pg)	30.34	27.78	26.35
MCHC (g/dL)	35.62	35.38	33.95
RDW (%)	13.7	16.5	18.6
Leukogram			
Total Leukocytes (mm ³)	4,160.00	5,440.00	2,160.00
Myelocyte (mm ³)	0.00	0.00	172.80 (8%)
Metamyelocyte (mm ³)	0.00	0.00	172.80 (8%)
Neutrophil (mm ³)	3,452.80 (83%)	4,841.60 (89%)	734.40 (34)
Lymphocyte (mm ³)	624.00 (15%)	272.00 (5%)	950.40 (44%)
Atypical Lymphocyte (mm ³)	0.00	0.00	64.80 (3%)
Monocyte (mm ³)	83.20 (2%)	163.20 (3%)	64.80 (3%)
Eosinophil (mm ³)	0.00	163.20 (3%)	0.00
Platelets (mm ³)	181,000	197,000	263,000
Biochemistry			
Creatinine (mg/dL)	1.01	ND	1.33
Aspartate aminotransferase (UI/L)	85.80	ND	769.10
Alanine aminotransferase (UI/L)	90.90	ND	182.40
C-reactive protein (mg/L)	75.49	157.36	157.11
Urea (mg/dL)	27.20	48.00	52.90
Albumin (g/dL)	ND	ND	2.31
Total Bilirubin (mg/dL)	ND	ND	1.21
Direct Bilirubin (mg/dL)	ND	ND	0.80
Indirect Bilirubin (mg/dL)	ND	ND	0.41
Calcium (mg/dL)	ND	ND	7.54
Alkaline phosphatase (U/L)	ND	ND	398.60
Lactate Dehydrogenase (U/L)	ND	ND	5,393.00
Potassium (mmol/L)	ND	ND	4.10
Sodium (mmol/L)	ND	ND	134.00

Hematological and biochemical profile, ND: Not Determined; MCV: Mean Corpuscular Volume; MCH: Mean microscopic examination and in the cultivation of tissues, fluids and body secretions⁷. Suggests culture in patients with suspected disseminated histoplasmosis. Extensions performed on material obtained from material collected from bone marrow stained by Giemsa can show the fungus in 50 to 75% of cases, helping in the diagnosis. In addition, there are other methodologies such as cultures of *H. capsulatum* that can take

Corpuscular Hemoglobin; MCHC: Mean Corpuscular Hemoglobin Concentration; RDW: Red Cell Distribution Width.

from one to three weeks, in addition to research of polysaccharide antigens of the fungus in urine and serum and research of serum antibodies, which are more elaborate and more expensive methods⁸. In the management of patients with AIDS and Histoplasmosis, severe or potentially serious patients requires early diagnosis and therapy, and as it is possible to diagnose *H. capsulatum* in the cytoplasm of monocytes



and neutrophils in peripheral blood smears in advanced stages of the disease^{2,9}, it becomes necessary for the clinical analyst to be attentive in observing yeast forms in order to obtain an early diagnosis, being able to enter the recommended medication, whose drug of choice is Amphotericin B should be administered in a total dose of 35 mg / kg¹⁰, as administered to the study patient. In conclusion, due to the high lethality of Histoplasmosis in HIV-positive patients, it is necessary to perform an early diagnosis with analysis of the patient's clinic, added to the biochemical and hematological laboratory findings, mainly due to the visualization of the fungus in the hemogram microscopy which presents as the most common diagnosis quick to start the indicated pharmacotherapy and reversal of the condition.

Study approved by the CEP of the University Positive protocol number 3.955.672.

Conflicts of interest

The authors declare no conflicts of interest.

4 REFERENCES

1 Papalini C et al. An Italian Case of Disseminated Histoplasmosis Associated with HIV. *Case Reports in Infectious Diseases*, 2019.

2 Passoni LF et al. Histoplasmosse disseminada como primeira manifestação de AIDS: um diagnóstico tardio demais. *Revista Médica do Hospital Federal dos Servidores do Estado*, 2003.

3 Nacher, M et al. Disseminated histoplasmosis in Central and South America, the invisible elephant: the lethal blind spot of international health organizations, 2016.

4 Rocha MM Severo LC histoplasmosse disseminada em pacientes com síndrome de imunodeficiência adquirida (SIDA). *Estudo de 25 casos. Rev. Inst. Med. trop. São Paulo*, 1994; 36: 167-170,

5 Wheat J. Endemic Mycoses in AIDS: a clinical review. *Clin. Microbiol. Rev.*, 1995; 8: 146-159.

6 Ramos IC. Achados clínicos laboratoriais como auxiliares no diagnóstico de histoplasmosse disseminada em pacientes febris com AIDS de hospital de referência do Ceará. 2008.

7 Koduri PR Chundi V DeMarais P Mizock BA Patel AR Weinstein RA Reactive hemophagocytic syndrome: a new presentation of disseminated histoplasmosis in patients with AIDS. *Clin. Infect. Dis.* 1995; 21: 1463-1465.

8 Passoni LF et al. Histoplasmosse disseminada como primeira manifestação de AIDS: um diagnóstico tardio demais. *Revista Médica do Hospital Federal dos Servidores do Estado*, 2003.

9 Attem MFT Passoni LFC Nakamura Y. Diagnóstico de histoplasmosse (*Histoplasma capsulatum*) pelo hemograma. Apresentação de um caso. *Rev. bras. hematol. hemoter.*, 22 (Supl.): 121 (Abstract 489), 2000.

10 Zambom LS. Caso Clínico–Hemograma com achado de fungos, 2014.